



# EQUINE HEALTH UPDATE

For Horse Owners and Veterinarians  
Vol. 20, Issue No. 2 – 2018

## A Tale of Foxtail – *Setaria* and its Effect on Equine Husbandry

By Taylor Huffman, DVM Student (Class of 2019)  
Edited by Amanda Farr, DVM, Dipl. ABVP – Equine

**Foxtails** are members of the *Setaria* genus in the grass family. The two most common species in Indiana are *Setaria viridis* (green bristle grass) and *Setaria pumila* (pigeon grass). The structure of these plants includes a grassy stem and a seed dispersing aid known as a diaspore, or spikelet, whose appearance resembles a fox's tail (Figure 1). This diaspore is made up of small barbs that cling to animal fur, skin, or clothing (Figure 2). Once the barb is caught and embedded, it is very difficult to remove.

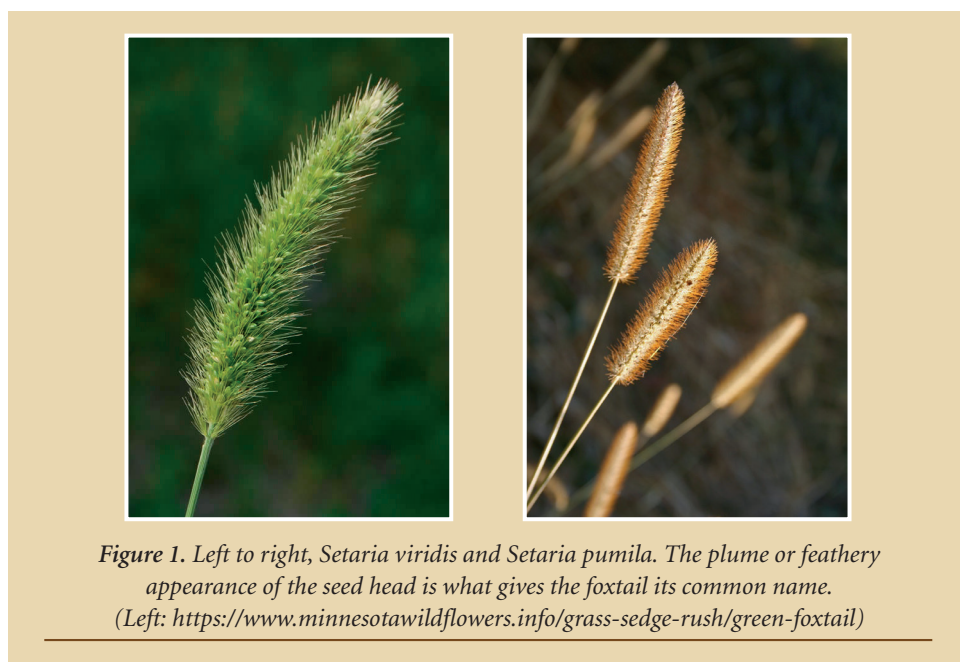


Figure 1. Left to right, *Setaria viridis* and *Setaria pumila*. The plume or feathery appearance of the seed head is what gives the foxtail its common name.  
(Left: <https://www.minnesotawildflowers.info/grass-sedge-rush/green-foxtail>)

In the horse world, foxtails are primarily a problem when they are present in hay (Figure 3). Foxtail grows best during times of drought as it is adapted to high temperatures and prolonged sun exposure. Horses can consume the stem of the foxtail without adverse effect, but when the diaspore (seed head) is consumed, the barbs detach and become lodged in the gums, lips, and other oral mucosa. Continued consumption of foxtail-contaminated hay or pasture leads to mucosal irritation with clinical signs including excessive salivation, difficulty in chewing/eating and a foul oral odor. In severe cases it can lead to complete inappetence due to inflammation and ulceration of the gums, tongue and other oral mucosal surfaces (Figure 4).

(continued on page 2)

### Contents...

#### Health

Equine Asthma ..... pg.7  
Joint Taps ..... pg. 4

#### Community Practice

Foxtails ..... pg. 1  
Young Horse  
Dentistry ..... pg. 3

#### News & Notes

Who's Who? ..... pg. 3

#### In Depth

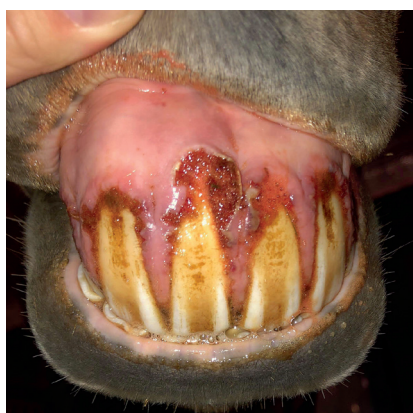Joint Taps ..... pg. 4

Visit [vet.purdue.edu/ePubs](http://vet.purdue.edu/ePubs) for more information on how to access the newsletter through our PVM ePubs app.

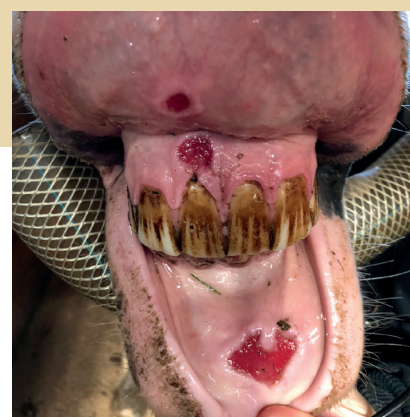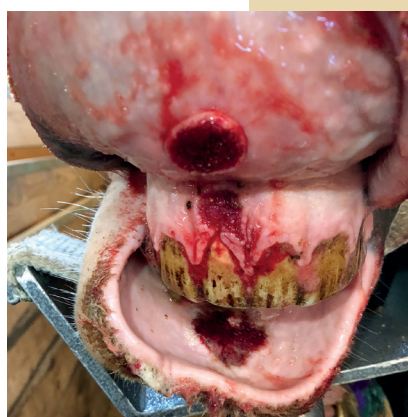## Foxtail – *Setaria* (continued from cover)

Once foxtail barbs are found in a horse's mouth, the treatment depends on the severity of the clinical signs and the horse's level of discomfort. The first step of treatment is the removal of the source, which is primarily hay. If the horse is not displaying signs of discomfort, this may be sufficient to resolve the problem. Once foxtail barbs have become lodged in the gums, lips, and tongue of your horse, they are difficult to remove completely. Studies have shown that following removal of the majority of the foxtail barbs, horses with associated oral ulcers completely resolve within 1-2 weeks. In cases of severe ulcerations, a rinse of the oral cavity using Listerine, combined with the mechanical removal of the barbs with gauze, towels or surgical debridement may be appropriate. While the barbs will eventually work themselves out, a horse with severe mucosal irritation will benefit from a sedated barb removal and flushing of the ulcers, allowing the affected tissue to begin healing more rapidly (Figure 5).


Foxtail consumption is a significant problem that affects the equine community, and it is important to remember that not all horses that consume foxtail-infested hay will be affected in the same way. Just as with bee stings or drug reactions, all horses respond uniquely to the foxtail they ingest, and rarely are all horses in a barn affected. It is important to remember to monitor roughage for the presence of foxtail and be prepared to treat affected animals if foxtail is fed intentionally or accidentally. As hay consumption begins or increases in late fall and winter, this is the most common time to see foxtail barb complications. For this reason, we recommend checking the oral cavity for foxtail ulcerations once hay is fed continuously and contacting your veterinarian if oral pain or ulceration is noted.



**Figure 4.** Foxtail barbs causing ulceration of the gum around the incisors. The “fuzzy” appearance is actually a mat of embedded foxtail barbs. (Photo courtesy of Dr. Amanda Farr)



**Figure 5.** Left: Foxtail barb ulceration of the lips and gums on a horse FOLLOWING sedated removal of most of the plant material. Right: Same horse, 5 days later. The gums and mucosa are less inflamed and the ulcers are healing. (Photos courtesy of Dr. Teresa Buchheit)



**Figure 2.** Microscopic barbs function to prevent the seed from detaching easily. They act similarly to drywall nails: easy to slide in, difficult to extract. ([https://en.wikipedia.org/wiki/Foxtail\\_\(diaspore\)#/media/File:Hordeum\\_murinum\\_retrorse\\_barbs\\_and\\_hairs\\_SEM.jpg](https://en.wikipedia.org/wiki/Foxtail_(diaspore)#/media/File:Hordeum_murinum_retrorse_barbs_and_hairs_SEM.jpg))



**Figure 3.** Above are two different presentations of foxtail in hay. The distinctive seed head makes foxtail readily identifiable.

### References:

- Douglas, B.J., Thomas, A.G., Morrison, I.N., Maw, M.G., 1985. The biology of Canadian weeds: 70. *Setaria viridis* (L.) Beauv. *Can. J. Plant Sci.* 65 (3), 669–690.
- Kutasi, O., Andrasofszky, E., Szenci, O., Bersenyi, A., Siller, I., Abonyi, T, 2018. Foxtail grass (*Setaria viridis*)-induced ulcerative stomatitis-gingivitis resembling viral vesicular stomatitis in horses. *Livestock Science.* 215 (2018) 41-45.
- “*Setaria*.” *Indiana Plant Atlas*, 28 August. 2018, <http://www.indiana.plantatlas.usf.edu/Genus.aspx?id=757>. Accessed 2 November 2018.



### New House Officers...



**Dr.** Fallon Segarra was raised in Clifton, Virginia. She received undergraduate degrees in Biology and Studio Art from Stanford University in 2012, and a Doctorate of Veterinary Medicine from Auburn University College of Veterinary Medicine in 2016. She began her veterinary career with a sports medicine

focused internship at Peninsula Equine Medical Center in Menlo Park, California and continued it with a second equine focused internship at the University of Missouri Veterinary Health Center in Columbia, Missouri. This past July marked the start of her Large Animal Surgery Residency at Purdue, for which she is extremely excited. Her professional interests include all aspects of large animal surgery, particularly equine and bovine orthopedics. In her spare time she enjoys hanging out with her fiancé and their (four!) dogs, riding her horse, and crocheting.




**J**ose Ignacio Goñi is a 2015 graduate of Rio Cuarto National University in Argentina. He was born and raised in General Levalle in the center of Argentina. He grew up riding horses on his family's farm and started working on a Polo horse breeding farm when he was 13 years old. He worked at the Equine Reproduction laboratory at the university, at Kawell, an equine hospital that is located in Buenos Aires, primarily in the Neonatal Intensive Care and Intensive Care Units, and at Park Equine Hospital during 2016. In 2017, he completed a sixth-month fellowship in internal medicine at Hagyard Equine Medical Institute in Kentucky, and then moved to the University of Georgia to complete a one-year rotating internship. In July 2018, he moved to Purdue University to start working as a first-year large animal internal medicine resident. He enjoys riding horses, playing soccer with friends, watching polo and soccer, being outdoors, and spending time with family and friends.



**Dr.** Kira Tyson is originally from Ridgecrest, California. She grew up with horses, dogs, birds, and reptiles. She has lived in Hawaii, Oklahoma, Washington, and Indiana. She received her undergraduate degree in Animal Science from Oklahoma State University, where she graduated with honors. She received her Doctor of

Veterinary Medicine from Purdue University. She remained at Purdue University for a Large Animal Internal Medicine specialty internship following graduation. It was during her internship that she developed a strong interest in large animal internal medicine. She completed her first year of residency at Washington State University. She is happy to be back at Purdue as a second year resident and to complete her training. Her interests include infectious disease, neurology, and neonatology. In her limited spare time, she enjoys hiking, camping, and kayaking.



**M**y name is Ahmed Khairoun. I was a senior clinician at the American Fondouk Working Equid Hospital in Fez, Morocco before I had an offer to start my Large Animal Internship at Purdue University. My ultimate goal is to become a surgeon to bring these skills back to Morocco in order to teach the next generation of Moroccan equine

vets. I am happy to know that I can use my knowledge to save equine lives, improve human livelihoods and improve equine surgery capability in my country.

I studied veterinary medicine at the IAV in Rabat, Morocco and after that I completed 3 equine internships. The first was at the American Fondouk in Fez, Morocco, the second was completed at the University of Lyon, France, and my last one was in private equine surgical practice at Milton Equine Hospital in Canada. During my internships on these 3 different continents, I have realized that each presents with its different challenges and I continue to learn a wide array of procedures.

Apart from equine surgery my main passion is playing violin, especially Andalusian music. Performing for people is a truly lovely feeling.

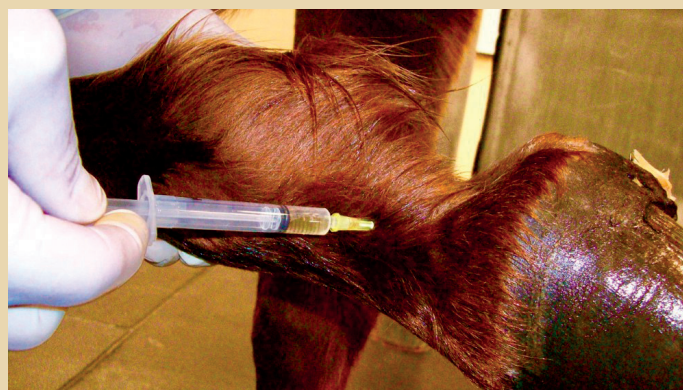# A Tap at a Time: Recognizing the Risks of Joint Injections

By Cody Schnur, DVM Student (Class of 2019) – Edited by Sarah Waxman, DVM, MS, Dipl. ACVS

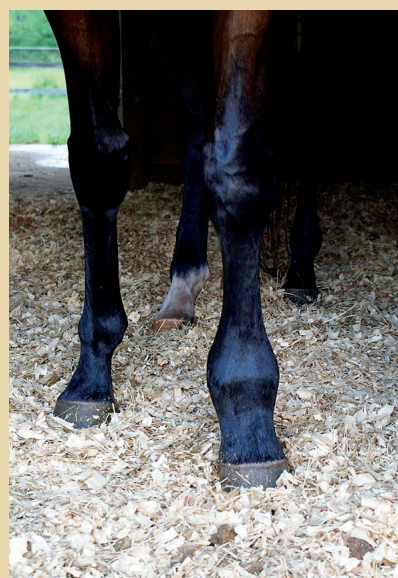**Arthrocentesis** (the process of injecting or “tapping” a joint) is commonly practiced by veterinarians for two key reasons: (1) to assist in diagnosing lameness by anesthetizing (“blocking”) the joint and (2) to therapeutically medicate an arthritic or painful joint (Figure 1). Joint injections can greatly improve an arthritic horse’s comfort by decreasing active inflammation and pain, improving the overall synovial (joint sac) environment, and protecting existing cartilage. Regardless of the benefits, there are potential complications that accompany arthrocentesis, including joint infection, joint flare, laminitis, and articular cartilage degeneration. It is imperative to understand these risks prior to having your horse’s joint(s) injected and to quickly recognize if these problems become apparent in your horse.

**Joint infection** (septic arthritis) is a rare complication of arthrocentesis that has been reported to occur at a rate of 2.1 in 10,000 injections (0.021%). Because infection occurs secondary to bacteria entering the joint during the procedure, the risk of infection is kept low when appropriate technique and preparation of the injection site is practiced and the horse is not excessively dirty, sweaty, nor has signs of skin infection (dermatitis). Interestingly, hair removal at the injection site is associated with an increased risk of contaminating the joint with hair fragments. These fragments can increase the chance for an infection so clipping before tapping is not recommended in most situations. Some veterinarians prefer to administer antibiotics into the joint such as amikacin or gentamicin along with the joint medication to help prevent bacterial contamination. Signs of joint infection can include pain, heat, stiffness, and swelling of the joint and surrounding soft tissues (Figure 2) as well as severe lameness most commonly within 2-5 days following an injection, however signs can be delayed up to a week or longer depending on what intra-articular medication was used. It is vital to recognize this risk as it can devastate joint function and potentially end a horse’s career or even life. This condition is treatable with a good chance for successful outcome as long as it is recognized and treated quickly.

**Joint flare** (reactive synovitis) is an inflammatory reaction that may occur in response to introducing any chemical substance (such as a medication) into a joint. Unlike a joint infection, a joint flare is not caused by bacteria, so it cannot be prevented with antibiotics. Signs are similar to joint infection and include mild to severe lameness, pain, and swelling of the joint typically within 24-48 hours of an injection. Some clinicians suggest administering a concurrent systemic NSAID (non-steroidal



*Figure 1. Arthrocentesis/joint tap procedure:  
(<https://medium.com/@equinelameness/so-what-exactly-are-joint-injections-in-horses-4af76709ebc8>)*



*Figure 2. Swelling of the fetlock joint:  
(<http://horsesinthesouth.com/blog/61609-dsc09679>)*

anti-inflammatory) at the time of tapping in order to reduce the risk for flare. This condition is much less threatening but does require urgent treatment.

**Laminitis** (inflammation of the hoof wall) might be linked to injecting high doses and/or frequent doses of corticosteroids (potent anti-inflammatories such as dexamethasone or triamcinolone) or use of corticosteroids in horses with pre-existing metabolic disease (such as Equine Cushing’s (PPID) or EMS).

*(continued on page 6)*



# Dental Exams in Young Horses

By Taylor Rietveld, DVM Student (Class of 2019) – Edited by Amanda Farr, DVM, Dipl. ABVP – Equine

Human dentistry begins with toddlers and equine dentistry should too! Young horses go through many phases of development which not only includes growing in size and maturity, but also advancing from baby (deciduous) teeth to adult (permanent) teeth. There are four arcades of teeth: two upper (maxillary) and two lower (mandibular) arcades in your horse's mouth. Between birth and around 2 ½ years of age, 24 baby teeth will erupt. These 24 teeth will be replaced with 36-44 adult teeth between 2 ½ and 5 years of age. With so many teeth erupting, many developmental problems can occur. Your veterinarian should perform an oral exam twice yearly during this developmental phase.

Equine incisors (the front teeth) erupt in the foal as early as prior to birth to several days following birth. The twelve (six upper and six lower) incisors erupt in a fairly specific pattern, with the central incisors erupting first, then the second incisors, and finally the third incisors. Veterinary students are taught the eruption dates of “6 days, 6 weeks, 6 months,” which are roughly accurate in most foals. The adult or permanent incisors erupt in a similar pattern from the central incisors to the outer incisors at 2 ½ years, 3 ½ years, and 4 ½ years. The permanent teeth erupt behind the deciduous (baby) teeth, and should force the deciduous teeth out. When this doesn't occur, the deciduous tooth is considered “retained”. Retained deciduous incisors can lead to permanent incisor irregularities (Figure 1).

In the interdental space (between the incisors and premolars) canine teeth develop. These erupt primarily in male horses but can also be present in mares. They are sharp, deep-rooted teeth and are frequently present in pairs. They are most common on the lower jaw. Canines that erupt on the upper arcades are often confused with the wolf teeth. The first premolar (behind or caudal to the canine) is called the “wolf tooth,” and due to potential interference with the bit it is commonly removed in young horses prior to training. They are not

present in all horses, although most zebras and zebra-crosses develop all four wolf teeth.

Premolars are the first 3 cheek teeth, per side, top and bottom. These also initially erupt as baby or deciduous teeth. They erupt between birth and 2 weeks of age. They are replaced by adult premolars between 2 and 3 ½ years of age. The adult teeth erupt directly above or below the baby teeth. If the baby tooth is not shed, the permanent tooth will push it out further, creating a “tall” tooth. This tall tooth can wear down the opposing (or opposite) tooth, creating a wave or inhibiting normal grinding of feed. Removal of the retained baby tooth, called a “cap,” can reduce this damage and allow normal development of the opposing teeth.

Molars are the back (caudal) three teeth on each side, top and bottom. These teeth only erupt as adult or permanent teeth. They typically appear between 9 months and four years of age. It is not uncommon for young horses around the age of 3 or 4 to develop swelling along their jaw as these teeth erupt, causing minor inflammation in the mandible.

When your veterinarian starts foal vaccinations around six months of age, please make sure they examine your foal's mouth. Additional abnormalities that can occur include a parrot mouth (over-bite) or a monkey mouth (under-bite) which may result in the incisors becoming overgrown due to abnormal grinding problems (Figures 2a, 2b).

Polydontia (which means additional teeth) is another abnormality that is most commonly present in the incisors and also behind the last molar of the upper (maxillary) arcade. In most cases, these are not noted until the adult teeth are erupting. Dental dysplasia is another deformity which involves the abnormal development of some aspect of the tooth. It can vary in the degrees of severity and may involve the crown, root, or the entire tooth.

*(continued on page 6)*

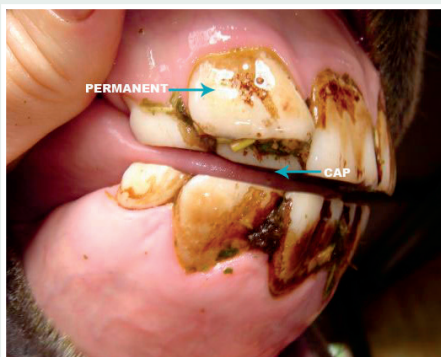


Figure 1. Retained deciduous incisor in a young horse. (<http://www.ggteef.co.nz/dental.html>)

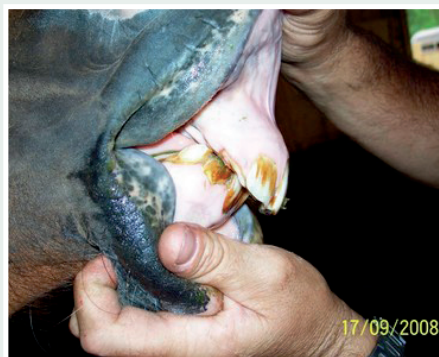

Figure 2a. Left: Severe over-bite (parrot mouth) in a young horse. (<http://www.mwveterinaryservices.com/equine-dentistry-photos.html>)



Figure 2b. Right: Under-bite in a mature horse. (Photo Courtesy of Dr. Stacy Tinkler).

## Dental Exams *(continued from page 5)*

It is clear that with the eruption of 24 baby teeth over the first two years of life, and their replacement with 36-44 adult teeth over the next 2-3 years, young horses have the opportunity for many dental developmental disorders. It is important to involve your veterinarian from 6 months of age onward. Once to twice annual exams can identify and correct many of these abnormalities that can occur during growth, leading to better dentition and fewer problems as they age and become working horses.

### References:

1. Tremaine, Henry, and Chris Pearce. "A Modern Approach to Equine Dentistry 4. Routine Treatments." In *Practice*, vol. 34, no. 6, 2012, pp. 330-347., <https://inpractice-bmj-com.ezproxy.lib.purdue.edu/content/34/6/330>
2. Taylor, William Timothy Treal. "Correction for Taylor Et Al., Origins of Equine Dentistry." *Proceedings of the National Academy of Sciences*, vol. 115, no. 40, 2 July 2018, doi:[http://www.pnas.org/content/115/29/E6707.short?casa\\_token=md8-E7Wj6T3wAAAAA:S2pVeoEqC3ikxijKvm2vK3Gbm917zRGvOpbDPzCjfwx62-lQx9RRHj9pcxmslrVVwNth6A-Z20h8ck](http://www.pnas.org/content/115/29/E6707.short?casa_token=md8-E7Wj6T3wAAAAA:S2pVeoEqC3ikxijKvm2vK3Gbm917zRGvOpbDPzCjfwx62-lQx9RRHj9pcxmslrVVwNth6A-Z20h8ck).
3. Easley, J. "Chapter 5, 8, and 12." *Equine Dentistry (Third Edition)*, Third ed., 2011

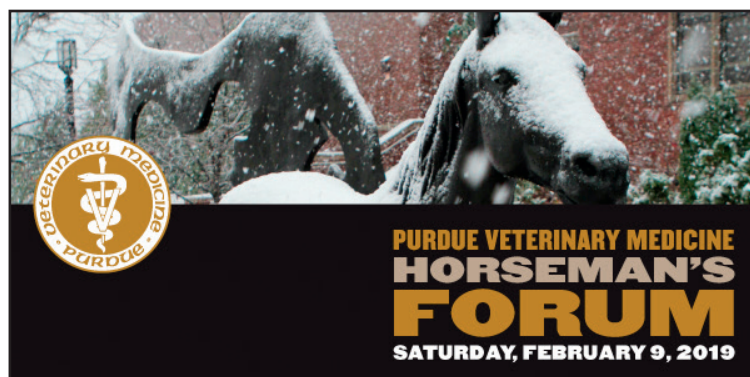## Joint Injections *(continued from page 4)*

Although the exact manner in which corticosteroids induce laminitis has yet to be determined, it is a theoretical risk of which owners should be aware. Signs of laminitis vary but may include an unnatural stance, reluctance to move, excessive weight shifting, a hot hoof wall, anxiety, and sweating. This condition is also considered an emergency and requires urgent treatment.

**Articular cartilage degeneration** (breakdown of joint cartilage) becomes a concern in horses that receive multiple, high-dose corticosteroid injections (products including Celestone® Soluspan®, Depo-Medrol®, and Vetalog®). Repetitive use of certain steroids and other steroid medications at high concentrations can have a detrimental impact on chondrocytes (cells that make cartilage), causing damage to and loss of the normal cartilage within the joint. Repeated doses of corticosteroids in vigorously exercised horses is particularly unfavorable

### References:

- Adams SB. (2012) *How to avoid complications following joint injections I: site preparation and selection of needles*. AAEP Proceedings. 58:425-429.
- Caron JP. (2005) *Intra-articular injections for joint disease in horses*. Veterinary Clinics of North America: Equine Practice. 21(3): 559-573.
- Clegg, P. (2012) *How to use intra-articular corticosteroids appropriately*. AAEP Proceedings. 58:464-466.
- Gillespie CC, Adams SB, Moore GE. (2016) *Methods and Variables Associated with the Risk of Septic Arthritis Following Intra-Articular Injections in Horses: A Survey of Veterinarians*. Vet Surg. 45(8):1071-1076.



## Registration Open for Purdue Horseman's Forum

The 2019 Horseman's Forum will take place on Saturday, February 9, 2019, in Lynn Hall on the Purdue University West Lafayette campus. This one-day program is designed to educate horse owners and equine industry professionals about current horse health issues, ranging from basic preventive health care and husbandry topics to state-of-the-art medical advancements. Topics for 2019 include: Leptospirosis, wound care, cardiology, acupuncture, lameness, nutrition, advanced imaging techniques, and an equine research update. Trailer safety and acupuncture demonstrations, along with large animal hospital tours will also be provided. Registration is now open! Group discounts are available for groups of 5 or more registering together. For more information, go to <https://vet.purdue.edu/ce/workshops.php> or contact Andrea Brown at [ahbrown@purdue.edu](mailto:ahbrown@purdue.edu) or (765) 494-0611.

due to the heightened risk of aggravating performance-related joint wear and tear. To avoid this phenomenon while achieving an optimal result, many veterinarians use lower corticosteroid doses in combination with a few days to weeks of rest following an injection.

### Take-home points:

- ☞ There are a few risks of having joint injections performed on your horse but fortunately most of them are exceedingly rare.
- ☞ Precautions taken by your veterinarian should decrease the odds of your horse getting an infection, flare, laminitis, or articular cartilage degeneration.
- ☞ Should your horse develop any of the above mentioned signs following a joint injection, you must contact your veterinarian immediately, as these problems are considered an emergency. For more information about joint injections please get in touch with your veterinarian on an elective basis.

# Asthma: A Common Problem in Racehorses and Cause of Poor Performance

By Drs. Laurent Couetil, DVM, PhD, Dipl. ACVIM and Kathleen Ivester, DVM, PhD, Dipl. ACVS

A study conducted by researchers from the Purdue University College of Veterinary Medicine at the Thoroughbred racetrack in Shelbyville, Indiana (Indiana Grand Racing & Casino) recently shed some light on a frustrating cause of decreased performance: horse asthma. Racehorse owners and trainers have known for some time that when horses have lots of mucus in the airways or cough, performance is typically not optimal. However, a study led by Dr. Laurent Couetil from PVM Equine Sports Medicine Center has shed new light on this disease that is for the most part “subclinical,” that is to say, difficult to detect because horses look healthy otherwise. They eat well and train fine, but they just can’t win!

The study was funded by the Grayson Jockey-Club Research Foundation and the state of Indiana and PVM research account funded by the total wager tax. The researchers hypothesized that exposure to high levels of dust was responsible for lung inflammation and that inflammation in turn would cause decreased performance. The goal was to enroll 100 Thoroughbred racehorses and to examine them approximately 1 hour after racing. This exam included a “lung wash” in order to collect cells from the deep lung to determine airway health. A few days later each horse was equipped with air sampling devices in order to collect dust around the horse’s nose for about 6 hours while the horse was going about its normal daily routine in the stall. The purpose was to compare dust exposure to lung health and evaluate the impact on race performance.

The researchers were able to examine horses after 98 races thanks to the tremendous support from 8 trainers. The finding showed that approximately 80% of racehorses had evidence of low grade inflammation in their lungs and that the greater the lung inflammation, the poorer horses performed. Importantly, they found that the greater the dust exposure, the worse the lung inflammation. It was not just any type of dust, but what is called “respirable dust” or particles that are less than 4 microns in diameter and are too small to be seen with the naked eye. Also, mold levels in airborne dust were associated with a certain type of airway inflammation. Because respirable dust

particles are small, they can penetrate deep into the lung, so it makes sense that exposure to high levels would be associated with lung irritation. The difficulty is that if you can’t see those small particles, it is difficult to know when levels are too high unless sophisticated equipment is placed on horses. Findings from this study were published in the Journal of Veterinary Internal Medicine last September (<https://onlinelibrary.wiley.com/doi/full/10.1111/jvim.15226>).

Additionally, the study examined the potential role of infectious agents such as viruses and bacteria. Preliminary results showed that common respiratory viruses were not associated with lung inflammation or performance. Work is still ongoing to examine the potential role of bacteria in lung inflammation.

Drs. Couetil and Ivester have again received funding from the Grayson Jockey-Club Research Foundation to continue this work by examining the effect of low-dust forage on lung health. They

started this second study at the Shelbyville racetrack this past summer and recruited 28 horses to be fed either regular hay or low-dust forage such as haylage or steamed hay for 6 weeks and evaluated lung health before and 3 and 6 weeks after being fed the different type of forages while measuring dust exposure of horses. The research team will be back to Shelbyville racetrack next summer 2019 to complete the study and they hope to be able to enroll a total of 60 horses. If you wish to participate in the study, please contact Dr. Couetil at the Purdue Large Animal Hospital 765-494-8548.

In conclusion, studies conducted by Purdue researchers showed that exposure to small dust particles is responsible for airway irritation in racehorses and in turn, this is likely to impact horse’s performance negatively. Future work is aimed at finding ways to mitigate dust exposure allowing horses to compete at their optimal level. **Stay tuned...**

#### References:

Ivester KM, Couëttil LL, Moore GE. An observational study of environmental exposures, airway cytology, and performance in racing thoroughbreds. *J Vet Intern Med.* 2018 Sep;32(5):1754-1762.





**EQUINE HEALTH UPDATE**

is published by:

**Purdue University**  
**College of Veterinary Medicine**  
**Equine Sports Medicine Center**  
1248 Lynn Hall  
West Lafayette, Indiana 47907-1248

**ADDRESS SERVICE REQUESTED**

Phone: 765-494-8548  
Fax: 765-496-2641  
[www.vet.purdue.edu/esmc/](http://www.vet.purdue.edu/esmc/)

With generous support of  
Purdue University's Veterinary  
Teaching Hospital and the College of  
Veterinary Medicine Dean's Office.

Please address all correspondence related  
to this newsletter to the address above.

Editorial Board:  
Drs. Couétil L., Hawkins J. and Tinkler S.

Design & layout by:  
Elaine Scott Design

EA/EOU



*The* **Equine Sports Medicine Center**

Purdue's Equine Sports Medicine Center is dedicated to the education and support of Indiana horsemen and veterinarians through the study of the equine athlete. The Center offers comprehensive evaluations designed to diagnose and treat the causes of poor performance, to provide performance and fitness assessments, and to improve the rehabilitation of athletic horses. Other integral goals of the Center are to pioneer leading-edge research in the area of equine sports medicine, to provide the highest level of training to future equine veterinarians, and to offer quality continuing education to Indiana veterinarians and horsemen. For more information visit our website:

[www.vet.purdue.edu/esmc/](http://www.vet.purdue.edu/esmc/)



Continuum© by Larry Anderson